

IMPACT 10 ON MEDICINE

Magnetic resonance imaging

One of the most striking applications of nuclear magnetic resonance is in medicine. **Magnetic resonance imaging** (MRI) is a portrayal of the concentrations of protons in a solid object. The technique relies on the application of specific pulse sequences to an object in an inhomogeneous magnetic field (a field with strength that varies inside the sample).

If an object (for instance, a tube of water or a human body) containing hydrogen nuclei is placed in an NMR spectrometer and exposed to a *homogeneous* magnetic field (a field that has the same value throughout the sample), then a single resonance signal will be detected. Now consider a flask of water in a magnetic field that varies linearly in the z -direction according to $\mathcal{B}_0 + G_z z$, where G_z is the field gradient along the z -direction (Fig. 1). Then the water protons will be resonant at the frequencies

$$\nu(z) = \frac{1}{2} \gamma_N (\mathcal{B}_0 + G_z z)$$

(similar equations may be written for gradients along the x and y directions). Exposing the sample to radiation with frequency $\nu(z)$ will result in a signal with an intensity that is proportional to the numbers of protons at the position z . This is an example of ‘slice selection’, the use of radiofrequency radiation that excites nuclei in a specific region, or slice, of the sample. It follows that the intensity of the NMR signal will be a projection of the numbers of protons on a line parallel to the field gradient. The image of a three-dimensional object such as a flask of water can be obtained if the slice selection technique is applied at different orientations.

A common problem with this technique is image contrast, which must be optimized in order to show spatial variations in water content in the sample. One strategy for solving this problem takes advantage of the fact that the relaxation times of water protons are shorter for water in biological tissues than for the

pure liquid. Furthermore, relaxation times from water protons are also different in healthy and diseased tissues. A T_1 -weighted image is obtained by obtaining data before spin-lattice relaxation can return the spins in the sample to equilibrium. Under these conditions, differences in signal intensities are directly related to differences in T_1 . A T_2 -weighted image is obtained by collecting data after the system has relaxed extensively, though not completely. In this way, signal intensities are strongly dependent on variations in T_2 . However, allowing so much of the decay to occur leads to weak signals even for those protons with long spin-spin relaxation times. Another strategy involves the use of *contrast agents*, paramagnetic compounds that shorten the relaxation times of nearby protons. The technique is particularly useful in enhancing image contrast and in diagnosing disease if the contrast agent is distributed differently in healthy and diseased tissues.

The MRI technique is used widely to detect physiological abnormalities and to observe metabolic processes. With **functional MRI**, blood flow in different regions of the brain can be studied and related to the mental activities of the subject. The special advantage of MRI is that it can image *soft* tissues (Fig. 2), whereas X-rays are largely used for imaging hard, bony structures and abnormally dense regions, such as tumours. In fact, the invisibility of hard structures in MRI is an advantage, as it allows the imaging of structures encased by bone, such as the brain and the spinal cord. X-rays are known to be dangerous on account of the ionization they cause; the high magnetic fields used in MRI may also be dangerous, but apart from anecdotes about the extraction of loose fillings from teeth, there is no convincing evidence of their harmfulness, and the technique is considered safe.

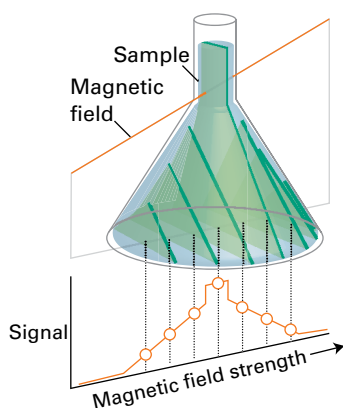


Fig. 1 In a magnetic field that varies linearly over a sample, all the protons within a given slice (that is, at a given field value) come into resonance and give a signal of the corresponding intensity. The resulting intensity pattern is a map of the numbers in all the slices, and portrays the shape of the sample. Changing the orientation of the field shows the shape along the corresponding direction, and computer manipulation can be used to build up the three-dimensional shape of the sample.

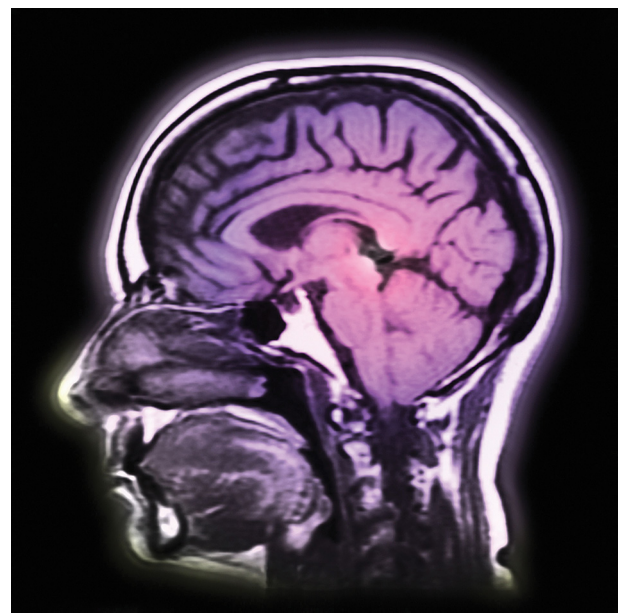


Fig. 2 The great advantage of MRI is that it can display soft tissue, such as in this cross-section through a patient's head. (Image source: Photodisc)